



**PATIENT**

Kylo Espinoza

**PRESENTING CLINICAL SIGNS**

History: Pre-Surgical EKG abnormal – showed tall R waves with an LAD. No murmur.  
-Abnormal PE/Chem/CBC/UA Results: CBC and Chem WNL, other than increased Glob 5.2.

**SPECIES**

Feline

**RADIOGRAPHIC FINDINGS** \*NOTE: Images submitted for supplemental cardiac information only.  
Possible cardiomegaly. No obvious evidence of CHF. Atypical thoracic confirmation distorts normal anatomy.

**BREED**

DSH

**ECHOCARDIOGRAM FINDINGS**

2D, m-mode, color flow and doppler imaging is available. The left ventricular wall is mildly increased in dimension. There is a diffusely hyperechoic endocardium consistent with fibrosis. Mild symmetric papillary muscle hypertrophy and remodeling. The right ventricle is subjectively normal in size and morphology. There is mild left atrial enlargement present. No right atrial enlargement present. Normal RVOT velocity. No TR. Normal LVOT velocity. There is no obvious systolic anterior motion (SAM) of the mitral valve present. Trace MR. There is no pericardial effusion noted. No pleural effusion appreciated. No obvious cardiac tumors.

**AGE**

7 years

**CARDIAC CHART**

**WEIGHT**

14.19lbs

FELINE CARDIAC PARAMETERS	BODY WEIGHT (kg)	HR (BPM)	IVSd (cm) (Moise, Pipers)	LVIDd (cm) (Moise, Pipers)	LVWd (cm) (Moise, Pipers)	FS (%)	EF (%)
NORMAL PARAMETER	-----	150-240	0.35-0.55	<2 (mean 1.5)	3.5-0.55	35-67	80-100
PATIENT	6.4	180	0.69	1.1	0.68	58	94
FELINE CARDIAC PARAMETERS	LA/AO (Boon)	LA/AO HEART BASE (Swe) (Abbott)	LA 2D short axis Base view (cm) (Abbott)		LVOT VEL (m/s)	RVOT VEL (m/s)	E max (m/s)
NORMAL	<1.5	<1.3	<1.2		<1.6	<1.3	<0.9
PATIENT	NM	1.4	1.4		1.1	0.9	NM

\*Note: All measurements based upon multi-modal images and methods. An average value is reported.

Adapted from June Boon, Veterinary Echocardiography, 1998

Abbott J & MacLean H JVIM 2006;20: 111-119, Moise et al. Am J Vet Res 47:1476, 1986. Pipers et al. Am J Vet Res 40:882, 1979.

**INTERPRETED BY**

Maggie Machen Lamy, DVM, DACVIM (Cardiology)

**IMAGING PERFORMED BY**

Sands Hill Mobile Veterinary Ultrasound

**HOSPITAL NAME**

Surf City Animal Hospital

**REFERRING VET**

Dr. Rudd

**INTERPRETATION OF THE FINDINGS & FURTHER RECOMMENDATIONS**

Hypertrophic cardiomyopathy (HCM) is a rule out diagnosis once a patient is deemed normotensive and euthyroid. Both should be ruled out in this case as contributing factors. The degree of disease is mild, with only mild LVH and mild LA dilation. This would indicate the risk for clinical issues is low at this time. No additional issues are identified.

**INVOICE**

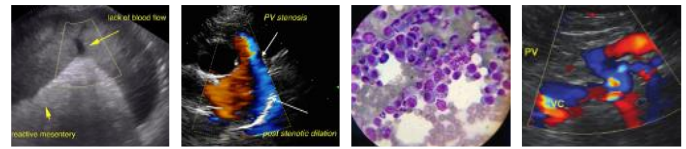
32287

No medications are indicated prior to significant atrial dilation. It is important to note that no medications have been shown to definitively alter long term outcome at this stage, particularly in the absence of SAM.

**DATE**

8/10/23

Monitor at home for any respiratory issues or signs of blood clot events (neurologic change, paralysis, etc.). Anesthetic risk is considered mild, however judicious fluid administration is advised if needed with careful RR/RE monitoring to screen for fluid overload. Additionally, drugs



**PATIENT**

Kylo Espinoza

that stimulate heart rate should be avoided unless clinically necessary (glycopyrrolate, atropine). Risk for complication with steroid use typically follows LA dilation, which in this case is mildly elevated. If needed, monitoring of RR/RE is advised particularly in the initiation phase.

**SPECIES**

Feline

**PLAN**

A screening blood pressure and T4 are recommended, then every 6 months lifelong.

**BREED**

DSH

A recheck echocardiogram is recommended in 6 months to assess for progression, sooner if any issues arise in the interim.

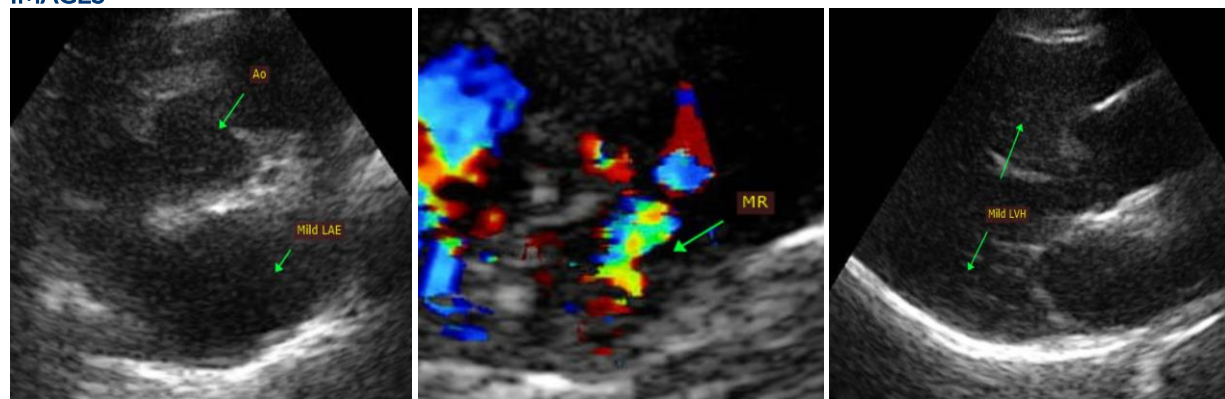
**SEX**

Male Neutered

**IMAGES**

**AGE**

7 years



**WEIGHT**

14.19lbs

**INTERPRETED BY**

Maggie Machen Lamy,  
DVM, DACVIM  
(Cardiology)

The information and recommendations provided are based on the images presented by the referring veterinarian. No evaluation can be communicated regarding pathology that was not visible in the image/video clips provided.

**IMAGING PERFORMED BY**

Sands Hill Mobile  
Veterinary Ultrasound

Thank you for this referral. This report was generated using transcription software, and minor dictation errors may be present. If the clinical or image interpretation does not parallel your findings or if I can be of any further assistance, please contact me.

**Maggie Machen Lamy, DVM**  
Diplomate of the American College of Veterinary Internal Medicine (Cardiology)  
info@sonopath.com

**HOSPITAL NAME**

Surf City Animal  
Hospital

**REFERRING VET**

Dr. Rudd

**INVOICE**

32287

**DATE**

8/10/23